



CrossMark



# Avulsion of Ampulla of Vater Secondary to a Blunt Abdominal Injury Treated with Pancreatoduodenectomy; A Case Report and Literature Review

Mustafa Ozsoy<sup>1\*</sup>, Ogun Ersen<sup>2</sup>, Zehra Ozsoy<sup>3</sup>, Sezgin Yilmaz<sup>2</sup>, Yüksel Arıkan<sup>2</sup>

<sup>1</sup>Department of General Surgery, Parkhayat Hospital, Afyon, Turkey

<sup>2</sup>Department of General Surgery, Faculty of Medicine, Afyon Kocatepe University, Afyon, Turkey

<sup>3</sup>Department of Internal Medicine, State Hospital, Afyon, Turkey

\*Corresponding author: Mustafa Ozsoy

Address: Department of General Surgery, Parkhayat Hospital, Afyon, Turkey

Tel: +900 544 7974871

e-mail: dr.mustafaoszoy@gmail.com

Received: September 29, 2017

Revised: January 20, 2018

Accepted: January 26, 2018

## ABSTRACT

The incidence of complex hepatobiliary injury secondary to blunt abdominal injuries varies between 3.4 and 5%. A 25-year old male patient underwent an urgent operation due to a motorcycle accident. During intraabdominal exploration, Grade 4 laceration was detected at the liver and bleeding was controlled through primary repair. In the postoperative seventh day, he was referred due to 1500 cc bile leakage from the drainage tube. During the operation, an extensive Kocher maneuver was done and the second part of duodenum was observed to be exposed to total avulsion from the head of the pancreas. Pancreatoduodenectomy was planned due to presence of ischemic changes in the second part of duodenum. In the postoperative follow-up, the abdomen was closed with a controlled abdominal closure procedure. The clinical findings of biliary tract injuries secondary to blunt abdominal injuries often manifest themselves late and early diagnosis is possible only with suspicion.

**Keywords:** Ampulla vater; Blunt abdominal trauma; Duodenal trauma; Avulsion.

Please cite this paper as:

Ozsoy M, Ersen O, Ozsoy Z, Yilmaz S, Arıkan Y. Avulsion of Ampulla of Vater Secondary to a Blunt Abdominal Injury Treated with Pancreatoduodenectomy; A Case Report and Literature Review. *Bull Emerg Trauma*. 2018;6(2):169-173. doi: 10.29252/beat-060212.

## Introduction

Injuries including biliary tracts, pancreas, and duodenum secondary to blunt abdominal injuries are extremely rare. Although there may be isolated biliary tract, duodenum, and pancreas injuries, complex hepatobiliary injuries including more than

one organ due to the severity of the injury can occur [1]. The incidence of complex hepatobiliary injuries ranges between 3.4 and 5% [2]. Hepatobiliary injuries involving the ampulla of Vater are associated with high mortality rates, depending on late diagnosis and, therefore, they are critical to diagnose [3]. In this study, we present a case of avulsion of the ampulla

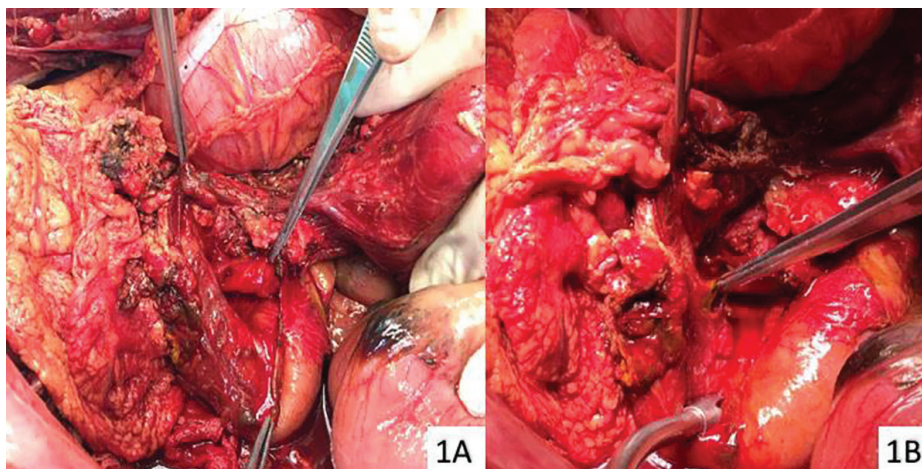
of Vater secondary to a blunt abdominal injury, who was treated with pancreatoduodenectomy (PD). Although, the retroperitoneal location of ampulla vater makes signs and symptoms typical of intraabdominal injuries less obvious. Early diagnosis and awareness of this type injury is lifesaving. We believe that our article providing additional contribution to the literature gives new perspective for the guiding to trauma surgeons.

### Case Report

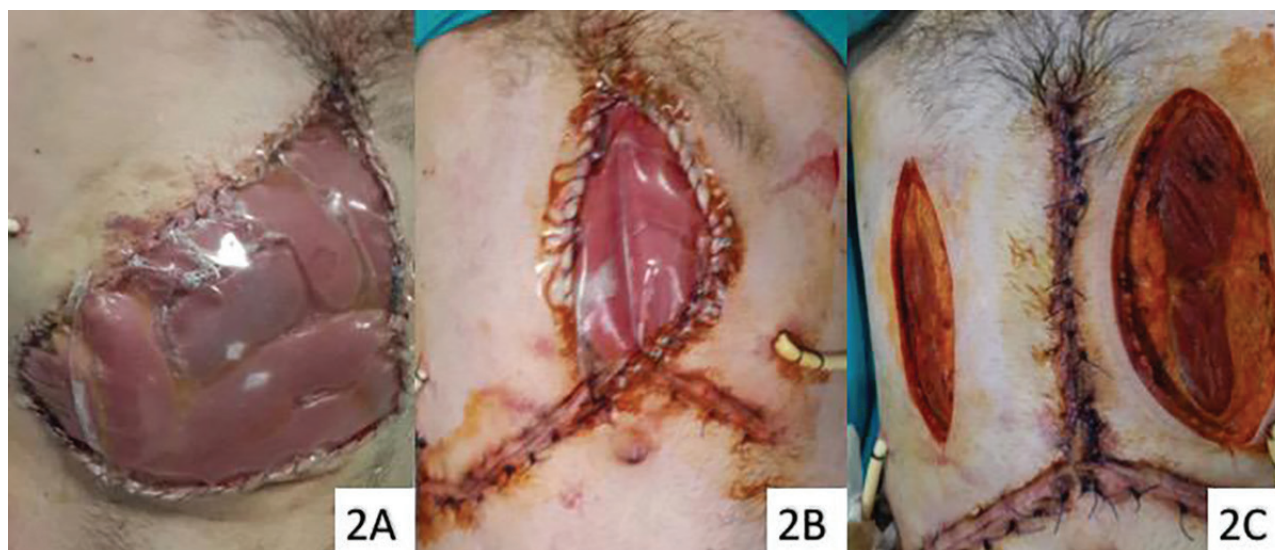A 25-year old male patient was referred to our clinic due to the biliary leakage. The patient had an emergency laparotomy at an external center 15 days prior due to a motorcycle accident. During intraabdominal exploration, Grade 4 laceration was detected at 6 and 7 segments of the liver and bleeding was controlled through primary repair. No additional pathology was found in the abdomen. In the postoperative third day, bile leakage was seen. The amount of the leakage increased daily, and the patient was referred on the postoperative seventh day for the presence of 1500 cc bile leakage from the drainage tube. The overall status of the

patient was moderate, and he was conscious and cooperative. The physical examination revealed that peritoneal irritation findings were positive. His body temperature was 38°C, pulse was 135 min, and blood pressure was 100/60 mmHg. Laboratory test results were as follows: aspartate transaminase (AST) 300 U/L; alanine aminotransferase (ALT) 400 U/L; total bilirubin 5 mg/dL; direct bilirubin 3 mg/dL; amylase 500 U/L; creatine: 1,2 mg/dL, hemoglobin (Hg) 10 g/dL, and leukocyte count (WBC) was  $15 \times 10^3/\mu\text{L}$ . The patient was scheduled for surgery since he had extensive septic intraabdominal fluid on emergent abdominal USG.

A written informed consent was obtained from the patient. About three liters of biliary fluid was drained during intraabdominal exploration. Primary suture segments were detected in the 6-7 liver segments. Bile leakage was not detected in the liver laceration area. However, a collection starting from the second part of duodenum and continuing to iliac junction, which was compliance with green bile, was found in the retroperitoneal region. Duodenum and the right colon were mobilized and the bilious collection was drained through the Kocher maneuver. The first, second, and third portion of the duodenum, and the



**Fig. 1.** Avulsion of the ampulla of Vater (A) and duodenal necrosis (B) following the extended Kocher maneuver.



**Fig. 2.** Closure of the open abdomen with multiple sessions (A-B-C)

head and neck of the pancreas was exposed with Kocher maneuver by dissecting the lateral peritoneal attachments. The gastocolic ligament was divided to entry into the lesser sac and the first portion of the duodenum, the medial aspect of the second portion of the duodenum, and the anterior surface of the pancreas were examined in detail. Meanwhile, the second part of duodenum was observed to be exposed to total avulsion from the head of the pancreas (Figure 1A). The common bile duct reimplantation using choledochoduodenostomy was not performed due to infection and tissue edema, ischemia. There for, pancreatoduodenectomy was then planned for the presence of ischemic changes in the duodenum (Figure 1B). Pylorus-preserving conventional pancreatoduodenectomy was performed. Open abdomen procedure was applied to the patient due to intestinal edema (Figure 2A). In the postoperative follow-up in the intensive care unit, intraabdominal edema was regressed, and the abdomen was closed with a controlled abdominal closure procedure (Figures 2B and C). The patient was discharged with healing and comes to regular control.

## Discussion

The etiology of injuries for the development of avulsions of the ampulla of Vater including the main biliary tract is unknown. The main theory explaining the pathogenesis of major biliary tract injuries is the sudden increase in the intra-ductal pressure. The acceleration–deceleration nature of blunt trauma causes the pancreas to be crushed against the first and second lumbar vertebrae. The compression of biliary tract and gallbladder between the vertebral column and the abdominal wall is also responsible for the sudden increase in the pressure. The injury appears at the point where the pressure of the fixed biliary tract is the highest [4]. They can be seen fully or partially. In a study by Rydell *et al.*, [5] complete lacerations were observed in 25 patients, and partial lacerations were observed in 31 lacerations.

Approximately 75 to 85 percent of blunt injuries to the duodenum and pancreas are caused by motor vehicle collisions. The mechanism is typically due to crushing of these fixed retroperitoneal organs between the vertebral column and steering wheel or seatbelt. The remainder of blunt duodenal and pancreatic injuries results from falls and assaults [4, 5]. Types of injuries including pancreatic duct injuries have the highest mortality rates. Avulsions of the ampulla of Vater are classified in duodenal injuries. Duodenal injuries are also divided into 5 types depending on their severity. In Type 1, there is a serosal injury without duodenal hematoma and perforation. Type 2 is the full-thickness duodenal injury without a pancreatic injury and duodenal hematoma at multiple sites. In Type 3, full-thickness duodenal injury is accompanied by a pancreatic hematoma. Type 4 includes duodenal injuries

including the ampulla and distal choledochus. Type 5 includes injuries such as duodenal devascularization and complex pancreatic duct injuries [6]. Diagnosis can be only made with the clinical suspicion in the early period. In the late period the evaluation of etiologic causes and the presence of pancreatitis and biliary acid may be informative. It is seen in about 10% of hyperamylasemia cases. In addition, severe pancreatitis may develop due to biliary and pancreatic juice into the peritoneal cavity. Also, there are cases presenting with a pancreatic pseudocyst in the late period [7, 8].

In our case, avulsion of the ampulla of Vater developed secondary to a blunt abdominal injury. The injury was duodenal Type 5, and the distal avulsion was observed according to the intra-ductal pressure increase theory. Although the preoperative diagnosis is difficult to be made, the presence of intraabdominal air, loss of psoas shadow signs, and the presence of scoliosis on direct abdominal X-ray may be helpful. In addition, the most useful diagnostic imaging modality is computed tomography with oral and intravenous radiopaque contrast media. Despite of adjunctive diagnostic methods, however, the diagnosis is usually made with a detail intraoperative exploration. During exploration, extensive duodenal mobilization is critical and the retropancreatic duodenum and pancreas should be evaluated [9].

In the detailed literature review, we could not obtain any algorithm how to manage extensive duodenal injury. However, many authors precise confident that treatment options often vary depending on the time of the definite diagnosis and also have to be planned in accordance with hemodynamic stability, associated injuries, and the location and extent of the injury [10]. In hemodynamically unstable patients or when the injury is extensive, damage control surgery should be kept in mind. The simple external drainage and T-tube drainage has been described more detailed in damage control surgery [11]. In hemodynamically stable patients, the surgeon should attempt a definitive surgical treatment. In case of early diagnosis and the biliary peritonitis is absent, the ampulla of Vater and vitality of duodenum are evaluated during this period. In case of a well-vitalized isolated biliary tract injury without a pancreatic duct injury, primary repair can be performed with stent or T tube. Stent or T tube generally would be used for six weeks. End-to-end anastomosis can be applied in adequate tissues for lesions of more than 50 % of biliary duct. No tension anastomosis is the most important point, otherwise, it may result in stenosis or fistulae. Many authors suggest Roux-en-Y anastomosis, with an incidence of stenosis of nearly 4 % [11]. On the other hand, in case of pancreatic injuries, pancreatojejunostomy and hepaticojejunostomy can be considered as the alternative treatment options. In the literature, there are four cases with ampullary cancer in whom the parts of the duodenum were excised and continuity was established by re-implantation of the pancreatic



duct. The re-implantation technique described by lee, could be performed in well-vitalized ampulla [12].

In case of late diagnosis, the clinical presentation of the patient is of utmost importance. Primarily, biliary drainage and gastrointestinal diversions are used to reduce septic shock. Simple gastrostomy, pyloric exclusion, and duodenal diverticulization are the management methods for the gastrointestinal diversion [13]. In case of late diagnosis, the duodenum and biliary tracts should be initially evaluated. Pancreatoduodenectomy should be performed in duodenal devascularization and pancreatic duct injuries. Most authors agree that whipple procedure for duodenal trauma is should be reserved for severe injuries of the head of pancreas and duodenum in whom others procedures with preservation of the pancreas and duodenum is not possible [13]. McKone has been proposed described specific conditions for a pancreatoduodenectomy for trauma. these situations are extensive devitalization of the head of the pancreas and duodenum in whom there is no chance of a repair, ductal disruption in the pancreatic head; avulsion to the ampulla of Vater [14]. It should be emphasized that Whipple procedure should always kept in mind for devitalized head of the pancreas and duodenum. However, the mortality and post-operative complication rate for a pancreaticoduodenectomy in severely injured and unstable patients are quite high. A pancreatoduodenectomy for trauma is the most demanding of all pancreatic resections due to hemodynamically unstable patients within coagulopathy, acidotic and hypothermic conditions. For these reasons, some authors recommend that a pancreaticoduodenectomy for trauma should always be performed as a two-stage procedure. The anastomoses could be completed 48 or 72 h later when the patient was stable [15]. Up to present, one hundred nine cases performed pancreaticoduodenectomy for trauma have been described by krige and the mortality rate is about 32.1% [13-15].

Our patient underwent an emergency operation upon the detection of liver injury causing hypotensive shock. Unfortunately, avulsion was failed to be

noticed during the intraoperative bleeding control. Postoperative bile leakage was attributed to possible intrahepatic biliary tracts injuries, which led to the progression of biliary peritonitis. During the re-exploration, the retropancreatic bile collection was detected and avulsion was detected through a detailed examination. Due to duodenal ischemia caused by delayed diagnosis, pancreatoduodenectomy was performed rather than the diversion techniques. If the main injury was diagnosed during the initial surgery, the diversion techniques could be applied and there should be no needed for major surgery such as pancreaticoduodenectomy. In such cases, postoperative feeding is also another concern. Malnutrition is common in patients postoperatively, and patients require nutritional support up to three weeks. Nutrition is often achieved by total parenteral nutrition, however more physiological enteral nutrition via a jejunal feeding tube can also be applied.

The biliary tracts injuries secondary to blunt abdominal injuries are extremely rare. Findings of biliary tract injuries secondary to blunt abdominal injuries often manifest themselves late and early diagnosis is only possible with only suspicion. These injuries are also associated with high morbidity and mortality rates. In the early diagnosis of avulsions of the ampulla of Vater, the experience of the clinician and equipment of the facility are critical. Therefore, avulsion of the ampulla of Vater should be considered in all cases of hepatobiliary injuries due to blunt abdominal injuries, and a detailed dissection should be performed. In case of late diagnosis, abdominal infection should be managed and delayed reconstruction should be the first-line treatment following biliary drainage in hemodynamically stable patients.

**Informed Consent:** Written informed consent was obtained from patient who participated in this case.

**Financial Disclosure:** The authors declared that this study has received no financial support.

**Conflicts of Interest:** None declared.

## References

1. Legros L, Quehen E, Bouguen G, Bretagne J-F. Avulsion of the papilla of Vater managed using a rendezvous technique and extra-anatomic drainage. *Endoscopy*. 2013;**45**(S 02):E397-E8.
2. Zago TM, Pereira BM, Calderan TR, Hirano ES, Fraga GP. Extrahepatic duct injury in blunt trauma: two case reports and a literature review. *Indian J Surg*. 2014;**76**(4):303-7.
3. Feng XF, Fan W, Shi CX, Li JH, Liu J, Liu ZH. Simplified pancreatoduodenectomy for complex blunt pancreaticoduodenal injury. *Chin J Traumatol*. 2013;**16**(5):311-3.
4. Akhrass R, Yaffe MB, Brandt CP, Reigle M, Fallon JW, Malangoni MA. Pancreatic trauma: a ten-year multi-institutional experience. *The American Surgeon*. 1997;**63**(7):598-604.
5. Rydell Jr W. Complete transection of the common bile duct due to blunt abdominal trauma. *Arch Surg*. 1970;**100**:724-8.
6. Azzam AZ. Avulsion of the common bile duct and ampulla of Vater after blunt abdominal trauma: Case report and review of the literature. *International Journal of Hepatobiliary and Pancreatic Diseases (IJHPD)*. 2011;**1**(1):1-5.
7. Scollay JM, Yip VS, Garden OJ, Parks RW. A population-based study of pancreatic trauma in Scotland. *World J Surg*. 2006;**30**(12):2136-41.
8. Flint Jr LM, McCOY M, Richardson JD, Polk Jr HC. Duodenal injury: analysis of common misconceptions in diagnosis and treatment. *Annals of surgery*. 1980;**191**(6):697.
9. Mirza B, Ijaz L, Iqbal S, Sheikh A. Partial avulsion of common bile duct and duodenal perforation in a blunt abdominal trauma. *APSP J Case Rep*.

- 2010;**1**(2):19.
10. Clavien PA, Barkun J, de Oliveira ML, Vauthey JN, Dindo D, Schulick RD, et al. The Clavien-Dindo classification of surgical complications: five-year experience. *Ann Surg.* 2009;**250**(2):187-96.
  11. Subramanian A, Dente CJ, Feliciano DV. The management of pancreatic trauma in the modern era. *Surg Clin North Am.* 2007;**87**(6):1515-32, x.
  12. Lee D, Zacher J, Vogel TT. Primary repair in transection of duodenum with avulsion of the common duct. *Arch Surg.* 1976;**111**:592-3.
  13. Krige JE, Nicol AJ, Navsaria PH. Emergency pancreatoduodenectomy for complex injuries of the pancreas and duodenum. *HPB (Oxford).* 2014;**16**(11):1043-9.
  14. McKone T, Bursch L, Scholten D. Pancreaticoduodenectomy for trauma: a life-saving procedure. *Am Surg.* 1988;**54**(6):361-4.
  15. Nicol AJ, Navsaria PH, Krige JE. Damage control surgery. *S Afr J Surg.* 2010;**48**(1):4-5.