



Femoral Shaft Fracture during Bungee Jump: A Case Report and Literature Review

Daniel Burchette^{1*}, Shreya Badhrinarayanan², Tim Hardwick¹, Rebecca Kampa³

¹SpR Trauma and Orthopaedics, Western Sussex Hospitals, Worthing Hospital (Western Sussex Hospitals NHS Foundation Trust), Lyndhurst Road, Worthing, BN11 2DH, UK

²Brighton and Sussex Medical School, BSMS Teaching Building, University of Sussex, Brighton, East Sussex, BN1 9PX, UK

³Western Sussex Hospitals, Worthing Hospital (Western Sussex Hospitals NHS Foundation Trust), Lyndhurst Road, Worthing, BN11 2DH, UK

*Corresponding author: Daniel Burchette

Address: SpR Trauma and Orthopaedics, Western Sussex Hospitals, Worthing Hospital (Western Sussex Hospitals NHS Foundation Trust), Lyndhurst Road, Worthing, BN11 2DH, UK. Tel: +1-77-64488600
e-mail: daniel@burchette.org.uk

Received: February 04, 2018

Revised: April 30, 2018

Accepted: June 04, 2018

ABSTRACT

Bungee jumping is a recreational sport that is accepted to carry a level of risk. We present the case of a femoral fracture sustained during bungee jumping and examine the published literature on bungee jumping-related injuries. A previously well 31-year old female performed a 200ft bungee jump from a crane. The apparatus was performed as expected and documented on the bystander video footage. As the bungee-cord became taut for the second time, there was an audible crack with accompanying scream. A closed, neurovascularly-intact injury was sustained to her right thigh. Radiographs revealed a comminuted mid-diaphyseal spiral femoral fracture, which was treated with intra-medullary nail fixation the following day. Following loss of position with proximal fragment flexion, the intramedullary nail was revised with open reduction and cerclage wiring 6 weeks later. Progression to clinical and radiological union was uneventful. Fatalities in bungee jumping are generally secondary to trauma as a result of equipment malfunction, user error, or related to pre-existing comorbidity². As no records are kept on bungee jumping injuries in the UK, reliable statistics are not available regarding the relative risks of this sport. We conclude that incidence of bungee jumping injuries is likely to remain low, but consider that improved recording of bungee jumping-related injury data will allow providers to give customers a realistic quantification of risk before engaging in this sport.

Keywords: Femoral Shaft Fracture; Bungee Jump; Sport.

Please cite this paper as:

Burchette D, Badhrinarayanan S, Hardwick T, Kampa R. Femoral Shaft Fracture during Bungee Jump: A Case Report and Literature Review. *Bull Emerg Trauma*. 2018;6(3):262-266. doi: 10.29252/beat-060314.

Introduction

Modern bungee jumping was born in Bristol, UK in 1979 when members of the Oxford

University Dangerous Sports Club jumped from the Clifton Suspension Bridge and has since flourished as a global commercial phenomenon. Despite the apparent dangers of bungee jumping few injuries

are reported in the medical literature. Ocular trauma is reported in multiple case reports [1, 2]. Other injuries sporadically reported include spinal facet joint dislocation with resultant quadriplegia, carotid artery dissection and non-fatal hanging injury [3, 4].

To the best of our knowledge, no previous case of femoral diaphyseal fracture has been reported as a consequence of bungee jumping, though we are aware of a case of comminuted subtrochanteric fractured proximal femur in a 23-year old female [5]. In addition, one case of femoral fracture is mentioned in the lay press, also in 22-year old female [6]. Sporadic anecdotal reports of other fracture can be found online. We herein present a case of femoral diaphyseal fracture after bungee jumping which was managed surgically.

Case Report

A previously well 31-year-old woman performed a 200ft bungee jump from a crane. She had no previous bungee jumping experience. The apparatus performed as expected, but as documented on bystander video footage, as the bungee cord becomes taut for the second time, there is an audible crack with accompanying scream. A closed, neurovascularly intact injury was sustained to her right thigh. Radiographs revealed a comminuted mid-diaphyseal spiral femoral fracture (Figure 1), which was treated with intra-medullary nail fixation the following day (Figure 2). Following loss of position with flexion of the proximal fragment, the intramedullary nail was revised with open reduction and cerclage wiring 6 weeks later. Progression to clinical and radiological union was thereafter uneventful (Figure 3). The causes of the initial failed fixation were identified to be a combination of an entry point that was too

anterior, combined with an implant that was too narrow in diameter. Poor initial reduction may have resulted from a reluctance of the original surgeon to disturb the fracture site, citing concerns about the periosteal blood supply.

The surgical technique employed was that of a standard femoral nail technique. The patient is placed supine on a traction table. Fluoroscopy is employed to gain as best reduction by manipulating the limb as can be achieved. Following skin preparation and draping, a small incision is made proximal to the greater trochanter. Through this, the greater trochanter entry point is placed with use of a guide wire, over which the entry reamer for the proximal portion of the nail is used.

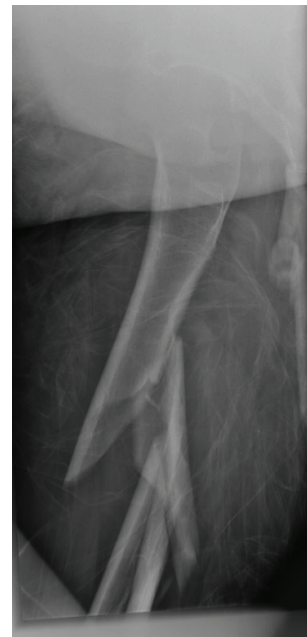

Fig. 2. Anteroposterior (AP) and Lateral radiograph post-failed fixation revealing a comminuted femoral fracture.

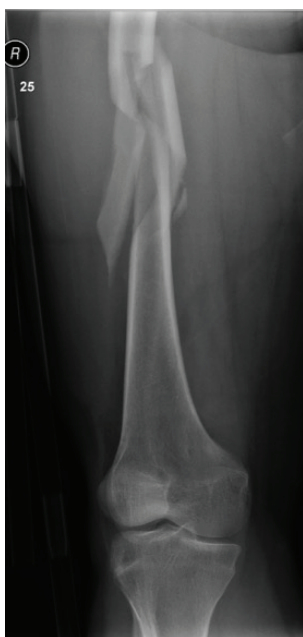


Fig. 1. Anteroposterior (AP) and Lateral radiograph of femoral fracture in the patient demonstrating a comminuted mid-diaphyseal spiral femoral fracture.

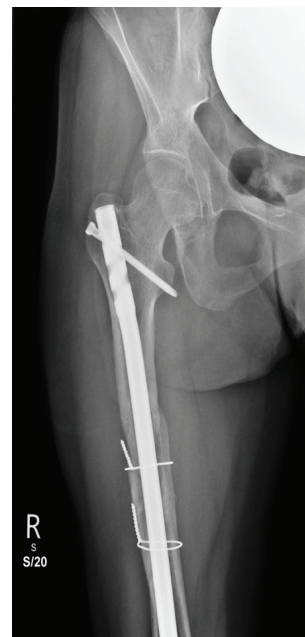

Fig. 3. Anteroposterior (AP) and lateral radiograph post-revision fixation demonstrating the intramedullary nail revision with open reduction and cerclage wiring.

A long, ball-tipped guide wire is then placed across the fracture site to be positioned in the middle of the distal femoral canal. Flexible reamers are passed, sequentially reaming the medullary canal to achieve the requisite internal diameter for the femoral nail. Care must be taken to ensure that the guide wire is not misplaced during this time, to avoid iatrogenic injury. In a grossly comminuted fracture, care must be taken that the reamer does not cause damage to surrounding structures. The largest sized nail that can be accommodated without reaming may be used in this situation. This technique can also be used to limit the physiological effects of increased intraosseous pressures and the potential for fat embolisation, particularly in those at increased risk from further insult, such as the multiply injured patient or the elderly.

Once the nail has been placed, proximal and distal locking screws are placed through the bone and the nail to prevent rotation or collapse of the construct. A variety of screw configurations may be selected based on fracture pattern and implant design. The proximal locking screws are placed with a jig attached to the nail. The distal locking screws are ordinarily placed under fluoroscopic guidance; though specific targeting systems are available. The final follow-up was by telephone at 18 months following her injury. The patient reported that she had been able to return to all her usual activities and had only occasional aching. The fracture had been observed to be radiologically united on follow up radiographs.

Discussion

Despite the apparent risks of bungee jumping, the rate of accidents and fatalities is thought to be comparable or lower than other high-risk sports [7]. A Survey of New Zealand adventure sports operators in 2003 [8] reported 62 bungee jumping related injuries with 3 'serious harm' events. The mean client injury rate per million participation hours (PMPH) was calculated at 477. This made it considerably safer than snow sports at 2,229.3 injuries PMPH, with 796 reported injuries, of which 112 were serious harm events. Horse riding was also significantly more dangerous, with an injury rate of 759.5 PMPH and 13 serious harm events in a total of 35 injuries. Sports that were safer than bungee jumping included white water rafting, black water rafting and mountain biking. Interestingly the perception amongst participants is that Skiing would be safer than bungee jumping [9].

A survey of 100 novice bungee jumpers analysed client body type (endomorph, ectomorph or mesomorph) and terminal fall angle, finding no correlation between injuries or symptoms reported and the terminal fall angle or body type. Of 100 jumpers, 42 reported some symptoms after the jump, primarily dizziness. There were 3 clients who reported symptoms enduring beyond 48 hours. This

suggests that injury or symptom rate may be under-reported [10].

Fatalities in bungee jumping are generally secondary to massive trauma as a result of equipment malfunction or user error, or related to a pre-existing medical co-morbidity [7]. We are aware of at least two cases of trauma related death in the UK [11, 12]. As no records are kept on bungee jumping injuries, there are no reliable statistics available regarding relative risks versus other extreme recreational activities [7]. A literature review was performed (search terms: Bungee; Exclusion criteria: no new injuries reported / Not bungee jumping related). The results can be seen in Table 1 [2, 4-5, 14-35]. The most frequently reported injuries in the scientific literature are ocular injuries, particularly retinal hemorrhage.

Based on video footage of the incident, the postulated mechanism of injury in our reported case is that, as the jumper enters free-fall for the second time, her trajectory has lateral motion and her legs are spread apart - the limit of the cord excursion is reached, the right leg is loaded preferentially to the left as her lateral trajectory continues. Her body turns, resulting in a traction-rotation injury. Different types of bungee harness are available. In this instance, two independent ankle harnesses appear to have been used with a full body back up harness applied to ensure restraint redundancy. Whilst this is in line with the best guidance available, it is unclear whether this injury would have been sustained with the more restrictive type of ankle harness, applying an even load through both legs (whilst making walking on the jump platform more difficult) or even using the body harness as the primary restraint [13]. Advice on using leg harnesses includes keeping legs positioned together whilst jumping, to avoid injury, as advised by the former British Elastic Rope Sports Association (BERSA) [13]. An inexperienced jumper may struggle to do this on their first jump. Following the dissolution of BERSA and the European Bungee Sports Association (EBSA) there are no British or European safety standards or regulation [13].

The injury presented in this case study is only the second occurrence of femoral fracture sustained whilst bungee jumping reported in the scientific literature and the third in all forms of literature. We conclude that the incidence of such injuries is likely to remain extremely low, but consider that a formal requirement to report bungee associated injuries from commercial ventures, together with the number of completed jumps would be beneficial in advising participants of the relative risks to help them make informed decisions about participation. In addition, it would allow for evaluation and improvement of harness design and procedural safety. If one type of harness proves to cause more or fewer injuries than other designs, this may affect harness choice for the occasional bungee jumper.

Conflicts of Interest: None declared.

Table 1. Summary of the literature review (search terms: Bungee; Exclusion criteria: no new injuries reported / Not bungee jumping related).

Authors	Journal	No.	Injuries	Notes	System Type
Gonzalez-Bermejo J, Straus C, Similowski T [14]	Eur Respir J. 2012 Jul;40(1):276-8	1	Diaphragmatic eventration	Reverse bungee jump	Pulmonary
Manos D, Hamer O, Müller NL [15]	J Thorac Imaging. 2007 Nov;22(4):358-9	1	Pulmonary haemorrhage		Pulmonary
Zhou W, Huynh TT, et al. [4]	J Vasc Surg. 2007 Nov;46(5):1044-6	1	Carotid artery dissection		Cardiovascular
Jain AK, Gaynon M [16]	N Engl J Med. 2007 Jul 19;357(3):e3	1	Macular haemorrhage		Ocular
Diniz JR, Arantes TE, et al [17]	Arq Bras Oftalmol. 2005 Nov-Dec;68(6):853-6.	1	Bilateral retinal haemorrhages		Ocular
Murphy D, O'Mahony M, et al. [18]	Respiration. 2006;73(1):113	1	Bilateral pneumothorax in Cystic Fibrosis		Pulmonary
FitzGerald JJ, Bassi S, White BD [19]	Br J Neurosurg. 2002 Jun;16(3):307-8	1	Subdural haematoma	Reverse bungee jump	Brain
Curtis EB, Collin HB [20]	Clin Exp Optom. 1999 Sep-Oct;82(5):193-195	1	Pre-retinal haemorrhage		Ocular
Louw D, Reddy KK, et al. [21]	J Neurosurg. 1998 Dec;89(6):1040-2	1	Midline disc herniations C5-7, with posterior longitudinal ligament disruption and spinal cord compression		Spinal
Krott R, Mietz H, Krieglstein GK [22]	Med Sci Sports Exerc. 1997 Jul;29(7):850-2	1	Orbital emphysema		Ocular
Kmucha ST [23]	Phys Sportsmed. 1996 May;24(5):70-3	1	Bilateral nasal bone fracture and left orbital floor fracture	Blunt facial trauma	Maxillofacial
Omololu AB, Travlos J [5]	Injury. 1995 Jul;26(6):413-4	1	Comminuted proximal femoral fracture		Orthopaedic
Van Rens E [24]	Br J Ophthalmol. 1994 Dec;78(12):948	1	Mononuclear haematoma, subconjunctival haemorrhage, small retinal haemorrhages		Ocular
Simons R, Krol J [25]	Lancet. 1994 Apr 2;343(8901):853	1	Macular haemorrhage		Ocular
Mees K [26]	Laryngorhinootologie. 1994 Mar;73(3):146-8	1	Tinnitus & decreased hearing in high frequency		ENT
Chan J [27]	Br J Ophthalmol. 1994 Mar;78(3):239	1	bilateral nasal and temporal subconjunctival haemorrhages. bilateral multiple parafoveal dot and blot haemorrhages		Ocular
Jain BK, Talbot EM [28]	Br J Ophthalmol. 1994 Mar;78(3):236-7	1	Intraocular haemorrhage		Ocular
David DB, Mears T, Quinlan MP [2]	Br J Ophthalmol. 1994 Mar;78(3):234-5	1	Purtscher's traumatic retinal angiopathy		Ocular
Habib NE, Malik TY [29]	Lancet. 1994 Feb 19;343(8895):487	1	Bilateral macular haemorrhage		Ocular
Innocenti E, Bell TA [30]	Eye (Lond). 1994;8 (Pt 6):710-1	2	Retinal haemorrhage, Transient Lateral Rectus dysfunction		Ocular
Filipe JA, Pinto AM, et al. [31]	Int Ophthalmol. 1994-1995;18(6):359-60.	1	Retinal hemorrhages in the right eye and a sub-internal limiting membrane hemorrhage		Ocular
Torre PR, Williams GG, et al. [32]	Ann Emerg Med. 1993 Nov;22(11):1766-7.	1	Common peroneal nerve palsy		Orthopaedic
Hite PR, Greene KA, et al. [33]	Ann Emerg Med. 1993 Jun;22(6):1060-3.	2	Anterior subluxation of C6 on C7 with quadriplegia. Non-fatal hanging injury.		Spinal
Jones, D [34]	Engineering Failure Analysis Volume 11, Issue 6, December 2004, Pages 857-872	1	Catastrophic apparatus malfunction; client death		Death
Kai-Wen Huang, Sheng-Jean Huang, et al. [35]	The American Journal of Emergency Medicine, Volume 19, Issue 4, July 2001, Pages 322-324	1	Anterior glenohumeral dislocation		Orthopaedic

References

- Hassan HM, Mariatos G, Papanikolaou T, Ranganath A, Hassan H. Ocular complications of bungee jumping. *Clin Ophthalmol*. 2012; **6**:1619-22.
- David DB, Mears T, Quinlan MP. Ocular complications associated with bungee jumping. *Br J Ophthalmol*. 1994; **78**(3):234-5.
- Hite PR, Greene KA, Levy DI, Jackimczyk K. Injuries resulting from bungee-cord jumping. *Ann Emerg Med*. 1993; **22**(6):1060-3.
- Zhou W, Huynh TT, Koungias P, El Sayed HF, Lin PH. Traumatic carotid artery dissection caused by bungee jumping. *Journal of vascular surgery*. 2007; **46**(5):1044-6.
- Omololu AB, Travlos J. Bungee jumping causing a comminuted proximal femoral fracture. *Injury*. 1995; **26**(6):413-4.
- Armstrong J. Girl smashes her leg in four places in bungee horror. Accessed: (July 6, 2011). Available from: <https://www.mirror.co.uk/News/UK/News>.
- Soreide K. The epidemiology of injury in bungee jumping, BASE jumping, and skydiving. *Med Sport Sci*. 2012; **58**:112-29.
- Bentley TA, Page S, Walker L. The safety experience of New Zealand adventure tourism operators. *J Travel Med*. 2004; **11**(5):280-6.
- Pedersen DM. Perceptions of high risk sports. *Percept Mot Skills*. 1997; **85**(2):756-8.
- Young CC, Raasch WG, Boynton MD. After the fall: symptoms in bungee jumpers. *Phys Sportsmed*. 1998; **26**(5):75-8.
- In: BBC News. Fatal bungee jump was 'accident'. (Accessed: February 25, 2005). Available from: news.bbc.co.uk/2/hi/uk_news/wales/south_west/4295059.stm.
- In: Daily Mail Online. Man dies after bungee jump accident. (Accessed: June 25, 2018). Available from: <http://www.dailymail.co.uk/news/article-135227/Man-dies-bungee-jump-accident.html>
- In: Health and Safety Executive (HSE). Operational Guidance on Bungee Jumping for Regulators. (Accessed: May 2015). Available from: [<http://www.hse.gov.uk/foi/internalops/og/og-00069.htm>]
- Gonzalez-Bermejo J, Straus C, Similowski T. A breathtaking reverse bungee jump. *European Respiratory Journal*. 2012; **40**(1):276-278.
- Manos D, Hamer O, Müller N. Pulmonary Hemorrhage Resulting From Bungee Jumping. *Journal of Thoracic Imaging*. 2007; **22**(4):358-359.
- Jain AK, Gaynon M. Images in clinical medicine. Macular hemorrhage from bungee jumping. *N Engl J Med* 2007 Jul 19; **357**(3): e3.
- Diniz J, Arantes T, Urbano R, Danda D, Almeida D. Ocular alterations associated with bungee jumping: case report. 2005.
- Murphy D, O'Mahony M, Logan P, Costello R, McElvaney N. Bilateral Pneumothoraces following a Bungee Jump in a Patient with Cystic Fibrosis. *Respiration*. 2006; **73**(1):113-113.
- Fitzgerald J, Bassi S, White B. A subdural haematoma following 'reverse' bungee jumping. *British Journal of Neurosurgery*. 2002; **16**(3):307-308.
- Curtis E, Collin H. Ocular injury due to bungee jumping. *Clinical and Experimental Optometry*. 1999; **82**(5):193-195.
- Louw D, Reddy K, Lauryssen C, Louw G. Pitfalls of bungee jumping. *Journal of Neurosurgery*. 1998; **89**(6):1040-1042.
- Krott R, Mietz H, Krieglstein G. Orbital emphysema as a complication of bungee jumping. *Medicine & Science in Sports & Exercise*. 1997; **29**(7):850-852.
- Kmucha S. Blunt Facial Trauma From a Bungee Jump. *The Physician and Sportsmedicine*. 1996; **24**(5):70-73.
- Van Rens E. Traumatic ocular haemorrhage related to bungee jumping. *British Journal of Ophthalmology*. 1994; **78**(12):948-948.
- Simons R, Krol J. Visual loss from bungee Jumping. *The Lancet*. 1994; **343**(8901):853.
- Mees K. Visual loss from bungee jumping. *Laryngo-Rhino-Otologie*. 1994; **73**(03):146-148.
- Chan J. Ophthalmic complications after bungee jumping. *British Journal of Ophthalmology*. 1994; **78**(3):239-239.
- Jain B, Talbot E. Bungee jumping and intraocular haemorrhage. *British Journal of Ophthalmology*. 1994; **78**(3):236-237.
- Habib N, Malik T. Visual loss from bungee Jumping. *The Lancet*. 1994; **343**(8895):487.
- Innocenti E, Bell T. Ocular injury resulting from bungee-cord jumping. *Eye*. 1994; **8**(6):710-711.
- Filipe JA, Pinto A, Rosas V, Castro-Correia J. Retinal complications after bungee jumping. *International Ophthalmology*. 1995; **18**(6):359-360.
- Torre P, Williams G, Blackwell T, Davis C. Bungee jumper's foot drop peroneal nerve palsy caused by bungee cord jumping. *Annals of Emergency Medicine*. 1993; **22**(11):1766-1767.
- Hite P, Greene K, Levy D, Jackimczyk K. Injuries resulting from bungee-cord jumping. *Annals of Emergency Medicine*. 1993; **22**(6):1060-1063.
- Jones D. Analysis of a fatal bungee-jumping accident. *Engineering Failure Analysis*. 2004; **11**(6):857-872.
- Huang K, Huang S, Lin T, Yen Z, Chen S. Anterior dislocation of the humeral head from bungee jumping. *The American Journal of Emergency Medicine*. 2001; **19**(4):322-324.

Open Access License

All articles published by Bulletin of Emergency And Trauma are fully open access: immediately freely available to read, download and share. Bulletin of Emergency And Trauma articles are published under a Creative Commons license (CC-BY-NC).