



Air Gun Pellet Injury to Internal Carotid Artery: A Case Report and Review of Literature

Abdul Hakeem¹, Deepak Kumar¹, Majid Anwer¹, Anurag Kumar¹, Abhishek Kumar¹

¹Trauma and Emergency, AIIMS, Patna, India

*Corresponding author: Majid Anwer

Address: Trauma and Emergency, AIIMS, Patna; Tel: +91 989967311;

e-mail: majidanwer1987@gmail.com

Received: February 22, 2024

Revised: March 4, 2024

Accepted: March 25, 2024

► ABSTRACT

Airgun injuries are prevalent in the pediatric population. The present study described a case of air gun pellet injury to the left carotid artery and its successful management. A 25-year-old man presented to the emergency department complaining that his son had accidentally injured him with an air gun pellet while playing. The X-ray cervical spine revealed a single foreign body (pellet) located directly anterior to the C5-C6 vertebra. A CT angiography of the neck showed a spherical hyperdense object just anterior to the C6 vertebral body on the left side, 3 mm posteromedial to the left common carotid artery, which was most likely a pellet foreign body. The patient was sent to operation theatre (OT) for exploration. There was a rent in the internal carotid artery with active bleeding. After exerting both proximal and distal control, the rent was closed. Close air gun injury could result in gunshot wounds, as in the present case. Plain X-rays in AP and lateral view are required. Nonoperative management could be employed in a restricted group of patients with satisfactory outcomes. Those who have vascular involvement will require surgical intervention.

Keywords: Airgun, Carotid artery injury, Neck injury, Computed tomography angiography, Vascular injuries.

Please cite this paper as:

Hakeem A, Kumar D, Anwer M, Kumar A, Kumar A. Air Gun Pellet Injury to Internal Carotid Artery: A Case Report and Review of Literature. *Bull Emerg Trauma*. 2024;12(2):95-98. doi: 10.30476/BEAT.2024.102081.1501.

Introduction

Air gun injuries are prevalent in the pediatric age group, and the injuries can range from mild to serious, including death [1-3]. The present study discussed a case of air gun pellet injury to the left carotid artery and its successful management.

Case Presentation

A 25-year-old man presented to the emergency

department with complaints of being accidentally hit with an air gun pellet by his son while playing. He was admitted to the hospital after an hour of injury. The child, while playing, accidentally shot his father, and the pellet passed through. The primary survey was essentially normal. His pulse was 94 bpm, and his blood pressure was 110/78 mm Hg. The secondary examination revealed a small entry wound on the left side of the neck zone 2, near the anterior triangle of the neck. There was no expanding hematoma or active bleeding from the

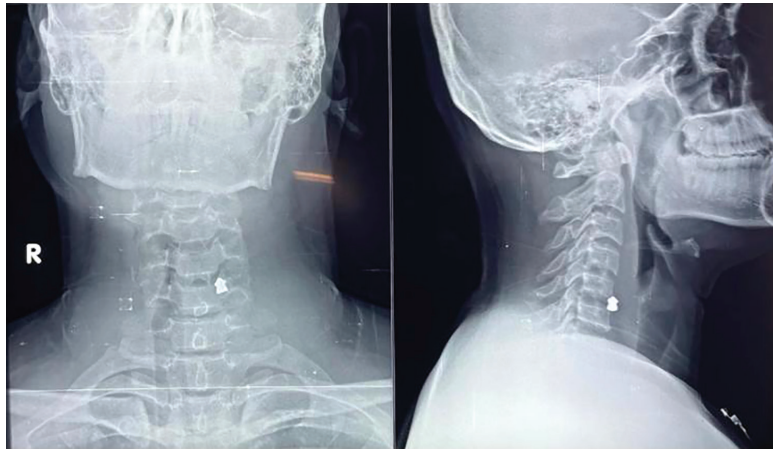


Fig. 1. AP and lateral views of the metallic foreign body (pellet)

neck wound. Baseline parameters included Hb=16.0 gm/dL, TLC=18.87, Plt=315, S.creat=0.90 mg/dL, Urea=26.4 mg/dL, Na:133.32, K=3.85, Ca=8.94.

The X-ray cervical spine revealed a single foreign body (pellet) right anterior to the C5-C6 vertebra (Figure 1). A CT angiography of the neck revealed a spherical hyperdense object just anterior to the C6 vertebral body on the left side, 3 mm posteromedial to the left common carotid artery, which was most likely a pellet foreign body. The poor opacification of the Internal jugular vein (IJV) in its entire course was noted as likely compressed. There was no evidence of contrast extravasation on angiography (Figures 2 and 3). Then, a final diagnosis of air gun pellet injury to the neck with vascular involvement was made, and the patient was scheduled for exploration.

The patient was sent to the operation theatre (OT) for exploration. A left-sided hockey stick incision was performed. Skin and subcutaneous tissue were divided in the line of incision. Sternocleidomastoid was identified and retracted laterally. A plane was formed anterior to the sternocleidomastoid (SCM) muscle. The internal carotid began bleeding profusely from the internal carotid artery. The bleeding was controlled using a peanut gauze ball. Dissection was performed proximal and distal to the bleeding vessel. Proximal and distal control was made with a vascular sling. The rent in the internal carotid artery (ICA) was repaired using Proline 6-0 (Figure 4). The IJV was looped and separated (Figure 5). A plane was made between the internal carotid artery and the IJV pellet to search the pellet. There was a spinous process fracture of C5, and the pellet was lodged in the scalene muscle, which was retrieved. The wound was irrigated with saline and closed in layers after pacing a subcutaneous drain. The patient was extubated and sent to the Intensive Care Unit (ICU) department. There was no post-operative weakness in either of the limbs. He developed left-sided mild weakness in the forearm muscle along with tingling, and numbness. He was sent to limb physiotherapy. Then, he gradually regained power and moved all four limbs equally. Finally, he was discharged, and now he is receiving regular follow-ups in OPD.

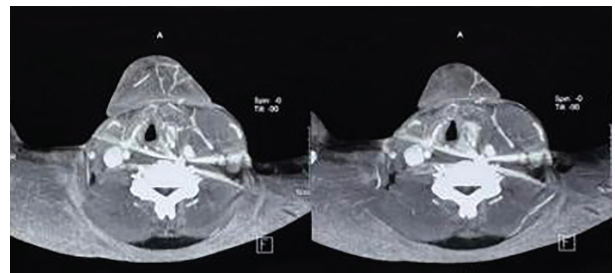


Fig. 2. T scan showing a foreign body in the neck

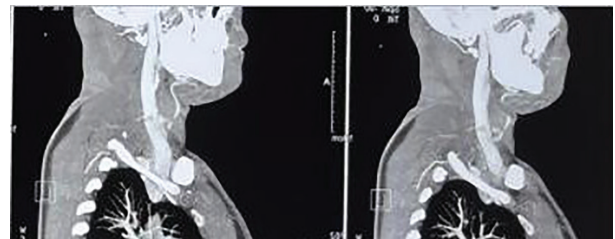


Fig. 3. Ct image showing poor opacification of IJV with no contrast leak

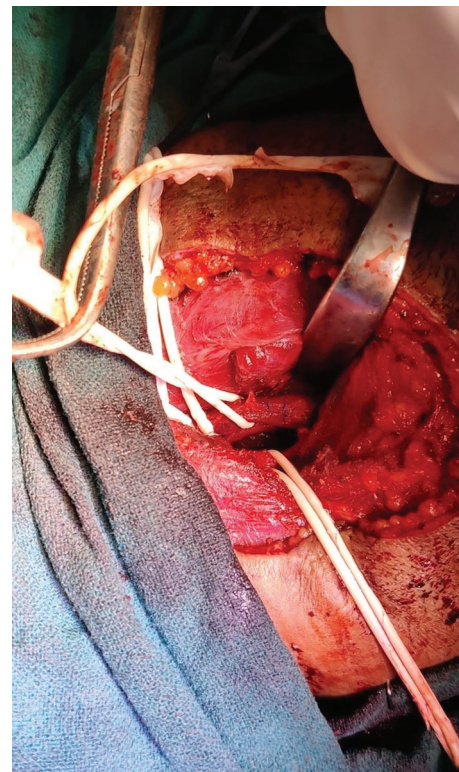


Fig. 4. Rent in the carotid artery was repaired

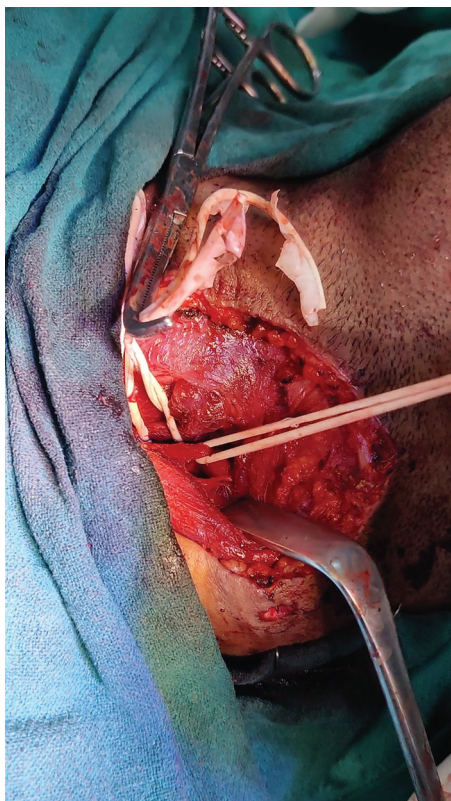


Fig. 5. Looped internal jugular vein

Discussion

In India, youngsters use air guns to aim at objects in the local Melas are gathering of people in countryside of India with lots of fun activities and parks. Traditionally, they have been used for recreational purposes. They have occasionally been used for bird hunting in villages or for recreational purposes at home. Air gun works by compressed air which propels the projectile such as BB or lead pellets [1, 3]. They have been seen as less deadly due to the absence of gunpowder in the firing mechanism. The projectile energy is equal to $\frac{1}{2}$ mass multiplied by velocity². As pellet mass is less, the major contribution of pellet energy comes from pellet velocity. Air gun pellets could cause serious injury when fired at a close range [1, 2]. The majority of such injuries have been reported in the oculocerebral region, followed by the neck [1]. The impact velocity required for pellet penetration varies with tissue type, ranging from 36 to 70 m/sec (120 to 230 ft./sec) for skin, 39 m/sec (130 ft./sec) for eyes, and 106

m/sec (350 ft./sec) for bones [4].

Close air gun injury could potentially inflict injury such as gunshot wounds, the same as in the present case. Plain X-ray in AP and lateral view were required. A contrast-enhanced CT of the neck with angiography was useful in identifying the extent of the injury [5]. Nonoperative management could be employed in a restricted group of patients with good outcomes [5]. Surgical intervention is required in those with vascular involvement, the same as the case in the present study. The intraoperative C arm is useful in identifying the exact location of the pellet [3]. The carotid artery injury was repaired, and the pellet was also retrieved.

The simple availability of such toys on online sites, along with the lack of adequate arms legislation for their possession, presents a potential dilemma for law enforcement. In India, air guns with a muzzle energy of less than 20 joules and a caliber of 0.177 inches or less do not require a license. These toys should be used with adult supervision and caution.

Air gun injury could cause serious injuries, particularly when fired at close range. Early diagnosis using X-rays or CT scans, as well as timely intervention could save lives.

Declaration

Ethics approval and consent to participate: Due ethical approval and consent has been taken.

Consent for publication: Consent has been taken from patient for publication.

Conflict of interests: The author declares no conflict of interest.

Funding: The author declares no grant for this research from any public funding agency, institutional grants.

Authors' Contribution: Abdul Hakeem was involved in treatment and writing of the case report. Deepak kumar helped in data collection and Anurag, Abhishek helped in writing manuscript. Majid Anwer did the final editing and critical analysis of the case report

Acknowledgments: I acknowledge Dr Anil Kumar

References

1. Bratton SL, Dowd MD, Brogan TV, Hegenbarth MA. Serious and fatal air gun injuries: more than meets the eye. *Pediatrics*. 1997;**100**(4):609-12.
2. Kuligod FS, Jirli PS, Kumar P. Air gun--a deadly toy?: A case report. *Med Sci Law*. 2006;**46**(2):177-80.
3. Abad S, McHenry ID, Carter LM, Mitchell DA. Carotid artery injury from an airgun pellet: a case report and review of the literature. *Head Face Med*. 2009;**5**:3.
4. DiGiulio GA, Kulick RM, Garcia VF. Penetrating abdominal air gun injuries: pitfalls in recognition and management. *Ann Emerg Med*. 1995;**26**(2):224-8.
5. van As AB, van Deurzen DF, Verleisdonk EJ. Gunshots to the neck: selective angiography as part of conservative management. *Injury*. 2002;**33**(5):453-6.

Open Access License

All articles published by Bulletin of Emergency And Trauma are fully open access: immediately freely available to read, download and share. Bulletin of Emergency And Trauma articles are published under a Creative Commons license (CC-BY-NC).