



Macular Branch Retinal Vein Occlusion as a Rare Complication of Periocular Scorpion Bite: A Case Report and Literature Review

Adel Hamid¹, Mohammad Shirvani¹, Mehrnoosh Maalagh^{1*}, Ali Rasti¹

¹Poostchi Ophthalmology Research Center, Shiraz University of Medical Sciences, Shiraz, Iran

*Corresponding author: Mehrnoosh Maalagh

Address: Poostchi Ophthalmology Research Center, Shiraz University of Medical Sciences, Shiraz, Iran.

e-mail: nooshinfard@gmail.com

Received: July 23, 2018

Revised: November 23, 2018

Accepted: November 25, 2018

► ABSTRACT

Scorpion bite has different manifestations in vital organs and may cause blindness secondary to involvement in the circulation of these vital organs. We report a case of abrupt vision loss and periorbital edema and redness due to scorpion bite in the eyebrow in an endemic region of southern Iran. A 45-year-old woman referred to the emergency room of our ophthalmology center due to abrupt vision loss and periorbital edema in her right eye. Involvement of ocular vasculature by localizing stroke due to the coagulative disorder caused by scorpion venom leads to retinal vein occlusion in this case. Management of BRVO was done with intravitreal injection of bevacizumab in the early phase. The outcome was complete vision recovery. To the best of our knowledge, this is the first case of macular branch retinal vein occlusion after scorpion bite.

Keywords: Scorpion bite; Macular branch retinal vein occlusion (BRVO); Ocular.

Please cite this paper as:

Hamid A, Shirvani M, Maalagh M, Rasti A. Macular Branch Retinal Vein Occlusion as a Rare Complication of Periocular Scorpion Bite: A Case Report and Literature Review. *Bull Emerg Trauma*. 2019;7(1):76-79. doi: 10.29252/beat-0701012.

Introduction

Scorpion bites are one of the most important environmental health hazards in Iran. The clinical manifestations of scorpion envenomation can be a challenge for emergency physicians since they are diverse, ranging from mild burning sensations at the sting site to critical fatal conditions[1]. Recognition of clinical presentations and complications of scorpion sting are invaluable as it could shed light on the way to therapeutic strategies. Scorpion bites often have dangerous consequences, including death due to cardio-circulatory failure, including acute pulmonary edema and also in rare cases cerebral vascular accidents. Another manifestation

is coagulative disorder which is disseminated commonly. These may be the result of a venom direct action or consequence of hemodynamic and blood coagulation disorders. Rare ocular manifestations of scorpion bites include transient blindness, cerebral blindness, and Bilateral Optic Neuropathy (BON) [2-4]. Herein, we present a case of macular Branch Retinal Vein Occlusion (BRVO) after the scorpion bite in the periocular region. To the best of our knowledge, this is the first report of periocular scorpion bite presented as BRVO.

Case Report

A 45-year-old woman referred to the emergency

room of our ophthalmology center with the chief complaint of abrupt vision loss and periorbital edema in her right eye. The patient reported that she was stung by a scorpion on her right eyebrow 2 days prior to admission and she had not received anti-venom. The patient brought the dead scorpion picture, and the species was confirmed by an entomologist as yellow scorpion (*Mesobuthus Eupeus*). The patient reported that she had not referred to the treatment center during the scorpion bite and had not presented with systematic symptoms; she also had not received an anti-venom. At emergency admission, the patient's vital signs were within normal range (BP:130/70mmHg, HR: 78bpm in the sinus rhythm, RR: 21 bpm, T:37.1°C oral temperature). The patient had no past history of systemic diseases such as hypertension, diabetes and coagulative disorders. External eye examination showed the site of scorpion

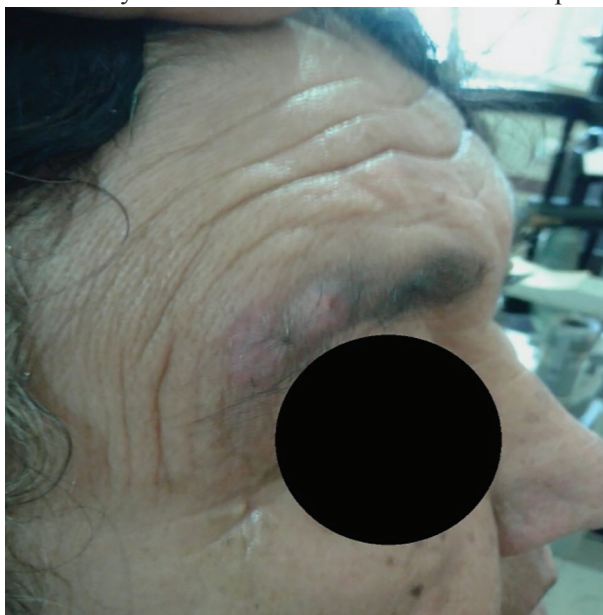

Fig. 1. External eye examination showed the site of scorpion bite had redness and swelling.

bite had redness and swelling (Figure 1). Visual acuity was 4/10 in the right eye and 10/10 in the left eye. No relative afferent pupillary defect was detected. There was no disturbance in the extraocular muscle function. The slit lamp examination had no remarkable finding. The examination of the fundus showed retinal edema and retinal hemorrhage in the superior arcade of the macula. The fundus photograph showed evidence of occlusion in the superior retinal vein branch and multiple areas of intra- and pre-retinal hemorrhages (Figure 2).

Spectral Domain Optical Coherence Tomography (SD-OCT) revealed that retinal thickness had increased in the temporal side and there were some hyper-reflective dots in the thickness of the retina in favor of retinal hemorrhage. Increase in the thickness of the retinal layers was evident in the extracellular edema subsequent to retinal vein occlusion (Figure

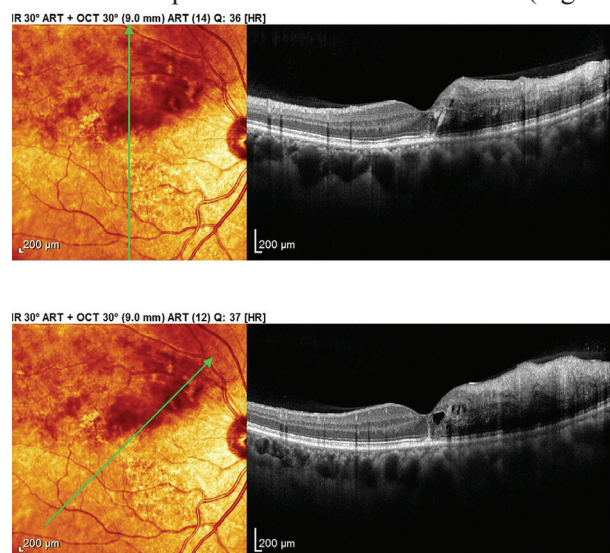


Fig. 2. Fundus photograph shows occlusion in superior retinal vein branch and multiple areas of Intra- and pre-retinal hemorrhages. SD-OCT shows extracellular retinal edema and increased retinal thickness

Table 1. Summary of the reported ophthalmologic manifestation cases following scorpion bite.

Author	Year	Country	Age	Sex (M ^a /F ^b)	Scorpion	ABP ^c (mmHg)	Ocular Manifestation	Outcome
Roussel [3]	1986	French	6	NR ^d	<i>Leiurusquinquestriatus</i>	NR ^d	Transient blindness	Complete Recovery
Annobilet. <i>al.</i> , [13]	1991	Saudi Arabia	3	M	<i>Nebo hierochonticus</i>	NR ^d	Transient Blindness	Resorption of the retinal haemorrhage
Thacker [14]	2002	India	17	M	<i>Buthus tumulus</i>	120/70	Bilateral Optic Neuropathy	Left side Persistent Blindness
Sadeghian [15]	2003	Iran	54	F	<i>MesobuthusEupeus</i>	NR ^d	Transient ophthalmoplegia	Complete Recovery
Senguptaet. <i>al.</i> , [8]	2009	French	40	F	NR ^d	90/60	Blindness	Cerebral blindness
Delma [10]	2012	Algeria	24	F	NR ^d	90/50	Blindness	Persistent Blindness
Hamid	2018	Iran	45	F	<i>Mesobuthus Eupeus</i>	130/70	Macular BRVO	Complete Vision Recovery

^aM: Male; ^bF: Female; ^cABP: Arterial Blood Pressure at hospital presentation; ^dNR: not reported

2) Hence, management of BRVO was done with intravitreal bevacizumab in the early phase (1 week later). Intravitreal injection of bevacizumab resolved the macular edema and vision recovery was achieved 2 weeks after the injection.

Discussion

Scorpion bites are reported in different parts of Iran [5]. There are two popular scorpion families in Iran: Hemiscorpidae and Buthidae [6]. Clinical signs and symptoms are not precisely determined for scorpion envenomation [5]. Most common clinical manifestations of scorpion bites are presented in the vital organs such as the Central Nervous System (CNS), Cardiovascular System (CVS), respiratory system, coagulation cascade, and endocrine system [2, 5-7]. There are few reports of ophthalmic manifestations of the scorpion bite. Table 1 shows the summary of the reported ophthalmic manifestation cases following scorpion bite. Ophthalmic involvements are mostly described as blindness. Two cases reported blindness as a consequence of brain infarction which leads to cortical blindness. One case presented with blindness without other neurologic symptoms after several episodes of the scorpion bite [3, 8, 9].

The authors mentioned several hypotheses to explain the blindness such as the direct effect of the scorpion venom on the optic nerve and hypersensitivity reaction to the scorpion venom or anti-venom [10]. In the present case, the patient did not receive an anti-venom. Another case presented with ophthalmoplegia after scorpion bite in the eyebrow [4]. Previous cases of the scorpion bite with ophthalmic manifestations seemed to have no direct effect on the orbital circulation. To the best of our knowledge, we here present a case of scorpion bite presented with the rare manifestation of macular BRVO two days after being bitten in the eyebrow on the same side. Coagulative disorders such as Disseminated Intravascular Coagulation (DIC) is one of the complications developed after scorpion bite [5]. In this case, findings are in favor of localized intravascular coagulation which

caused an occlusion in the branch of the retinal vein. Despite previous cases, decreased vision is related to localized stroke happened in ophthalmic circulation, affecting the ocular vascular directly without the accompaniment of other neurologic or vascular accidents in other organs. The scorpion venom activates coagulation cascade through its low molecular weight polypeptides in different pathways. The main messengers for induction of the coagulation and complement cascade are cytokines such as endothelin and neuropeptide Y [11]. The mechanisms indicated explain the reported case.

Based on previous studies, the first line treatment for acute BRVO is anti-VEFG treatment. Anti-VEFG treatment had promising results in the macular edema and visual acuity improvement. Regardless of the cause of the retinal vein occlusion, this treatment was considered for this patient and the result was encouraging [12]. This is the first case presented as macular BRVO due to scorpion bite. Given the age, medical history, and health status of the patient, other causes of vascular accident with exclusive ophthalmic presentation were unlikely to be the case.

In conclusion, in endemic regions it should be kept in mind that less dangerous scorpion species might present with local non-fatal effects, due to the characteristics of the scorpion toxin. As mentioned in this case quick action in treating eye problems is very helpful with good prognosis.

Declaration of patient's consent: The authors acknowledge that they have obtained all appropriate patient consent forms. The patients were assured that their names and initials would not be published and due efforts would be made to conceal their identity, but anonymity cannot be guaranteed.

Acknowledgement

The authors would like to thank Shiraz University of Medical Sciences, Shiraz, Iran and also Center for Development of Clinical Research of Nemazee Hospital and Dr. Nasrin Shokrpour for editorial assistance.

Conflicts of Interest: None declared.

References

- Alkahlout BH, Abid MM, Kasim MM, Haneef SM. Epidemiological review of scorpion stings in Qatar. The need for regional management guidelines in emergency departments. *Saudi Med J*. 2015;**36**(7):851-5.
- Udayakumar N, Rajendiran C, Srinivasan AV. Cerebrovascular manifestations in scorpion sting: a case series. *Indian J Med Sci*. 2006;**60**(6):241-4.
- Roussel L. Scorpionism complicated by transient blindness. Apropos of a case. *Med Trop (Mars)*. 1986;**46**(4):409-11.
- Sarkies JW. Ophthalmoplegia following a scorpion bite. *Br J Ophthalmol*. 1951;**35**(8):502-4.
- Sophie R, Campochiaro PA. Treatment of Macular Edema following Branch Retinal Vein Occlusion. *US Ophthalmic Review*. 2013;**6**(2).
- Pipelzadeh MH, Jalali A, Taraz M, Pourabbas R, Zaremirkabadi A. An epidemiological and a clinical study on scorpionism by the Iranian scorpion *Hemiscorpis lepturus*. *Toxicon*. 2007;**50**(7):984-92.
- Dehghani R, Fathi B. Scorpion sting in Iran: a review. *Toxicon*. 2012;**60**(5):919-33.
- Eze CO, Onwuekwe I, Ekenze O. Stroke as a rare consequence of scorpion sting and scorpion ingestion: A case report from South East Nigeria. *Annals of Tropical Medicine and Public Health*. 2014;**7**(4):202.
- Sengupta S, Dhanapal P, Ravindran RD, Devi N. Cerebral blindness after

- scorpion sting. *J Neuroophthalmol.* 2009;**29**(2):154-5..
10. Gadwalkar SR, Bushan S, Pramod K, Gouda C, Kumar PM. Bilateral cerebellar infarction: a rare complication of scorpion sting. *J Assoc Physicians India.* 2006;**54**:581-3.
 11. Delma K. About a case of blindness following scorpion envenomation. *Journal of Venomous Animals and Toxins including Tropical Diseases.* 2012;**18**(4):478-82..
 12. Bordon L, Paredes W, Pacheco R, Graneros N, Tolosa C, Galarza G, et al. Intracerebral Hemorrhage Secondary to Scorpion Toxin in the Northwest of Argentina; A Case Report. *Bull Emerg Trauma.* 2018;**6**(3):253-6..
 13. Annobil SH, Omojola MF, Vijayakumar E. Intracranial haemorrhages after Nebo hierochonticus scorpion sting. *Ann Trop Paediatr.* 1991;**11**(4):377-80.
 14. Thacker AK, Lal R, Misra M. Scorpion bite and multiple cerebral infarcts. *Neurol India.* 2002;**50**(1):100-2.
 15. Sadeghian H. Transient ophthalmoplegia following envenomation by the scorpion *Mesobuthus eupeus*. *Neurology.* 2003;**60**(2):346-7.

Open Access License

All articles published by Bulletin of Emergency And Trauma are fully open access: immediately freely available to read, download and share. Bulletin of Emergency And Trauma articles are published under a Creative Commons license (CC-BY-NC).