



Talocalcaneal Coalition Including Open Comminuted Calcaneal Fracture; A Case Report and Literature Review

Uldis Berzins¹, Gloria Maria Hohenberger^{1*}, Ines Vielgut¹, Renate Krassnig¹, Bore Bakota², Franz Josef Seibert¹

¹Medical University of Graz, Department of Orthopaedics and Trauma, Graz, Austria

²Morrison University Hospital, Swansea, UK

*Corresponding author: Gloria Hohenberger

Address: Medical University of Graz, Department of Orthopaedics and Trauma Surgery, Auenbruggerplatz 5, 8036 Graz, Austria.

Tel: +43-676-8885049

e-mail: hohenberger.gloria@gmail.com

Received: October 1, 2018

Revised: November 25, 2018

Accepted: December 1, 2018

▶ ABSTRACT

Tarsal coalition is an often unrecognised cause of foot and ankle pain and represents a congenital osseous, cartilaginous or fibrous connection between two or more tarsal bones. Fractures in combination with tarsal coalitions are rarely described in the literature. We report the case of a 43-year-old male patient with a talocalcaneal coalition who sustained an open comminuted calcaneal fracture and a closed transverse cuboid fracture. Due to the asymptomatic tarsal coalition and the already firmly fixed subtalar joint, the patient was treated with open reduction and internal fixation (ORIF) with satisfactory outcomes instead of ORIF in combination with subtalar arthrodesis. Ten months after the trauma, the patient was satisfactory and could return to his regular work. There is currently no evidence for the gold standard treatment of calcaneal fractures with combined tarsal coalitions. Due to the satisfactory results of this case, authors conclude that in case with prior asymptomatic coalitions, singular ORIF without subtalar arthrodesis may be performed.

Keywords: Calcaneonavicular coalition; Talocalcaneal coalition; Tarsal coalition; Calcaneal fracture; Cuboid fracture.

Please cite this paper as:

Berzins U, Hohenberger GM, Vielgut I, Krassnig R, Bakota B, Seibert FJ. Talocalcaneal Coalition Including Open Comminuted Calcaneal Fracture; A Case Report and Literature Review. *Bull Emerg Trauma*. 2019;7(1):80-83. doi: 10.29252/beat-0701013.

Introduction

Tarsal coalition represents an abnormal osseous, cartilaginous or fibrous connection between two or more tarsal bones and is an often unrecognised cause of foot and ankle pain [1-4]. Forming about 90% of all junctions, talocalcaneal and calcaneonavicular coalitions are its most common subtypes [2-4]. Here, the talocalcaneal form commonly concerns the middle subtalar facet, whereas the anterior and posterior facets are rarely involved [1, 5]. Besides

occurring as an isolated anomaly, tarsal coalitions may co-exist with further congenital malformations [1]. Further, they appear bilaterally in 50% of all cases and a slight male predominance has been described [3, 4]. Tarsal coalitions concern less than one percent of the population. However, the real prevalence remains unknown since their majority are asymptomatic [1, 4, 6]. By contrast, fractures in the context of tarsal coalitions are an even more rare entity, sparsely described in the literature. We report the case of a 43-year-old male patient

with a talocalcaneal coalition who sustained an open comminuted calcaneal fracture and a closed transverse cuboidal fracture which were both treated with open reduction and internal fixation (ORIF).

Case Report

A 43-year-old man, who had fallen through a roof hatch from the height of about 4 metres, was brought to our institution. On arrival, the patient had a Glasgow Coma Scale (GCS) score of 15 and was hemodynamically stable. During inspection of the left foot, an approximately three-centimetre-long lacerated wound at the medial margin of the heel was found. Via its probing, the calcaneus could be reached. The peripheral blood circulation, motor and sensory functions were intact. The performed polytrauma computer tomography (CT) revealed an unstable burst fracture of the first lumbar vertebra. Additional radiographs revealed a fracture of the tip of the left lateral malleolus without dislocation (Figure 1A), a comminuted fracture of the left calcaneus (Sanders classification type 2A). The CT scan of the left ankle showed the comminuted calcaneal fracture including one of the fracture lines reaching

the calcaneocuboid articulation, a transverse fracture of the cuboid (Figure 1B) without gross dislocation and the fracture of the tip of the lateral malleolus. The radiography showed a talocalcaneal coalition (Figure 1C). Further, the talocalcaneal coalition was seen to involve the anterior and middle facets of the subtalar joint (Figure 2).

Initially, the fracture of the first lumbar vertebra was reduced and fixed with dorsal spondylosis (TH12-L2) and kyphoplasty (L1). The wound at the medial side of the heel received extensive debridement and the bone was reduced. The defect was closed and a lower leg orthosis was applied. During the hospital stay, the patient received intravenous antibiotic therapy with 2g cefazolin twice per day. Fourteen days after the injury the soft tissues were settled and the definitive treatment of the calcaneal and cuboid fractures was conducted. The osteosynthesis was performed using an extended L-shaped lateral approach to the calcaneus starting from the base of the fifth metatarsal to the lateral border of the Achilles tendon. Dissection was performed sharply to the bone. The calcaneocuboid joint proved to be hypermobile with elongated and lax ligaments. First, the osteosynthesis of the cuboid was performed

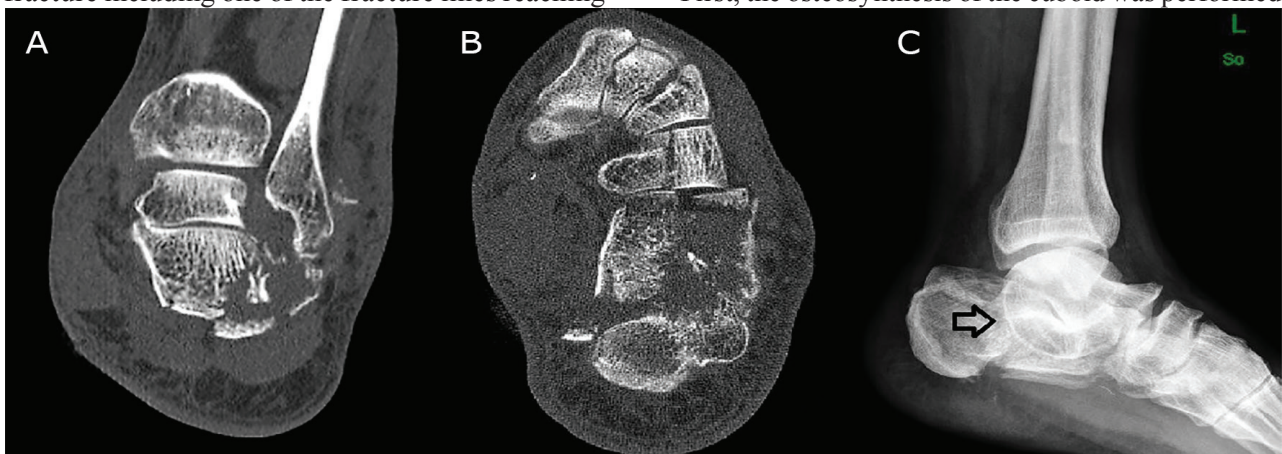


Fig. 1. Axial computerized tomography (CT) scan depicting the fracture of the tip of the lateral malleolus (A); and a comminuted calcaneal fracture and a transverse fracture of the cuboid (B); The lateral ankle radiograph shows the calcaneal fracture with the talocalcaneal coalition including the “C-Sign” (arrow) (C).

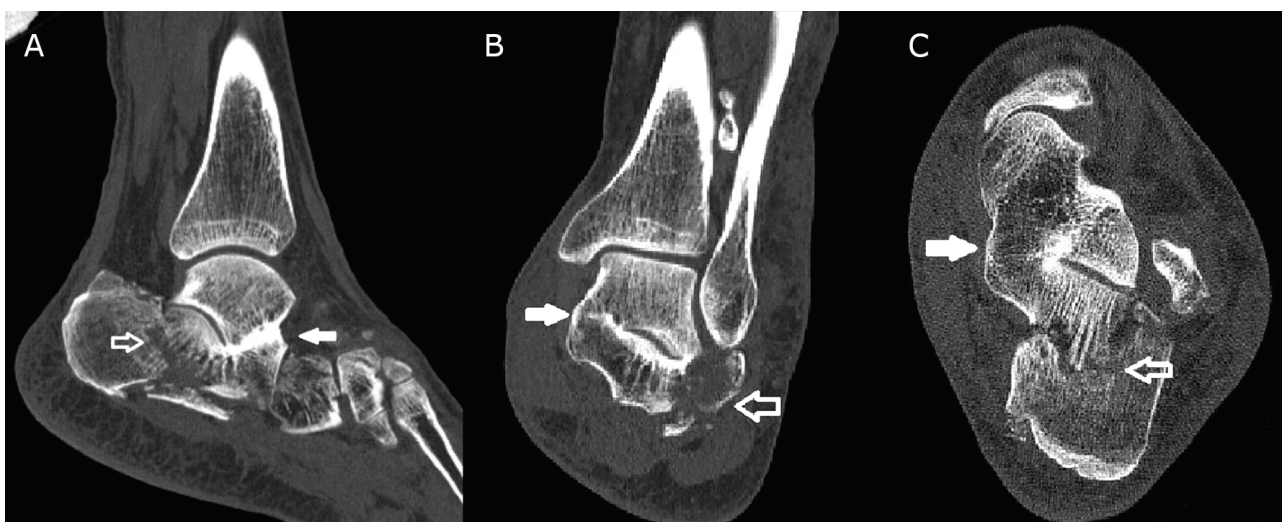

Fig. 2. The sagittal (A), coronal (B) and axial (C) ankle CT scans showing the calcaneal fracture (white arrow) and the coalition of the middle facet (filled white arrow) of the subtalar joint.

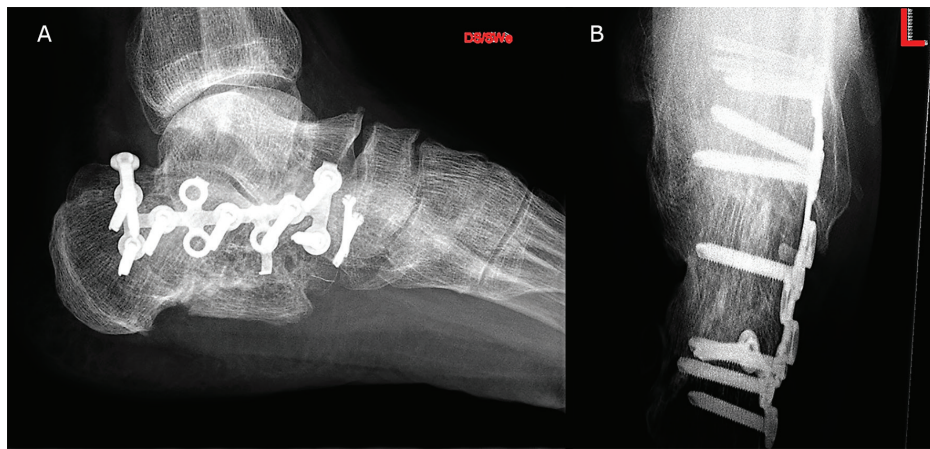


Fig. 3. The lateral (A) and axial (B) calcaneus radiographs are showing the plate fixation of the calcaneus 10-month post-surgery.

with 3.0 mm cannulated screws. The anterior calcaneal fragment was hereditary fixed to the talus through a synostosis and the fragment holding the posterior joint facet was also connected to the talus with a firm, partially ossified joint capsule so the joint space was not visible and movement in the subtalar joint was impossible. There were no anatomic reference points for the fracture reduction, so the shape of the calcaneus was reconstructed according to the uninjured contralateral calcaneus. The reduction was obtained by manual traction and was held in the correct length and physiological valgus with temporary K-wire fixation through the calcaneal tuberosity. Due to the asymptomatic nature of the coalition and because of the already firmly fixed subtalar joint, the decision was made in favour of fracture fixation and against a subtalar arthrodesis. The fixation was made with a Synthes® locking calcaneal plate (Synthes GmbH, Solothurn, Switzerland) which was customized to match local anatomy and fixed with 3.5 mm LCP screws. The wound was closed primarily and a cast was applied until wound healing. Physiotherapy started after wound healing. Non-weight-bearing was ordered for eight weeks under therapy with subcutaneous application of Lovenox 40 mg once per day. The postoperative course remained unremarkable, the operative wounds healed primarily, the patient was adequately mobilised and left the hospital after 20 days. Antibiotic treatment with 2g cefazolin twice a day was continued for 21-day post trauma. Step-wise weight-bearing could be started eight weeks' post-surgery. Ten months after trauma, the patient had almost reached the same range of motion in comparison to the contralateral side (Figure 3). He reported pain (visual analogue score: 2) at the lateral malleolus only after long walks and had returned to his regular work. His American Orthopaedic Foot and Ankle Society (AOFAS) Ankle-Hindfoot Score was at 87 points.

Discussion

Tarsal coalitions, also referred to as congenital tarsal

synostoses, represent a rare origin of hindfoot pain. At this, talocalcaneal coalitions, which are among the most common subtypes, usually involve the middle part of the subtalar joint [5]. In our case, the talocalcaneal coalition concerned the anterior and middle facets of the subtalar joint and this is, to our knowledge, the first reported case of this combination. The described patient showed a unilateral coalition. Regarding diagnostic features to detect tarsal coalitions, conventional radiographs in two planes are the first step. Due to their interpretation with respect to tarsal junctions, various secondary radiographic signs, as for example the “C-sign”, have been described. These formations develop as a result of the coalitions' alteration of the hindfoot joints' biomechanics. Conventional X-rays are in most of the cases sufficient to depict calcaneonavicular coalitions. However, the recent literature states that the talocalcaneal forms generally require cross-sectional imaging since their assessment can be difficult on conventional radiographs. In contrast, in our case, the initial X-rays had already provided an overview of the coalition. Magnetic resonance imaging (MRI) may be an additional resource for differentiation between osseous, fibrous or cartilaginous formations [5].

Since the combination of tarsal coalitions and fractures of the adjacent bones is minimally described, no guidelines for their therapy are available. Up to now, we only found five cases and all of them involved different injury patterns [4, 5, 7-9]. Concerning conservative treatment examples, Moe *et al.*, [5] reported on an MRI-detected partial coalition of the posterior subtalar facet in association with two stress fractures of the calcaneal tuberosity. Therefore, partial weight-bearing was recommended. Wähnert *et al.*, [4] presented the case of a young patient with acute ankle sprain and a CT-proven, non-displaced fracture of a talocalcaneal coalition which was located between the middle subtalar facet and the sustentaculum tali. Pain-adapted weight-bearing was advised. Regarding the operative treatment, Hughes and Brown [7] published the case of a talus fracture in combination with an osseous talocalcaneal coalition.

The fracture could only be reduced and fixed after excision of the coalition. Kim and Berkowitz [8] reported about a fibrous middle facet talocalcaneal coalition with an intraarticular calcaneal fracture in a 15-year-old male patient. Due to a high depression of Bohler's angle, ORIF was conducted. In this case, authors did not opt for excision of the coalition due to a lack of pre-existing symptoms. The patient had returned to sport activities such as surfing and running at 4-year follow-up and showed an equal range of motion bilaterally. In comparison to this case, our patient showed a bony coalition with a fixed subtalar joint. Excision was also not performed due to not existing pre-traumatic symptoms. As in Kim and Berkowitz [8], our patient could return to daily activities. Chodos and Cambell⁹ described an intra-articular calcaneal fracture with bony middle facet coalition in a 50-year-old male. As the patient reported about pre-traumatic mild hindfoot pain and degenerative changes of the subtalar joint could be observed intraoperatively, subtalar arthrodesis and ORIF of the calcaneus were performed. Similar

to this case, the described patient was a middle-aged male with a coalition of middle facet of the subtalar joint, however, in our case the coalition was asymptomatic, and the injury was more complex including open calcaneal fracture and an additional fracture of cuboid. In Chodos and Cambell [9], the patient returned to his pre-injury workplace and described only mild discomfort due to his calcaneus fracture. Due to the asymptomatic tarsal coalition and the already firmly fixed subtalar joint, our patient was treated with ORIF with satisfactory outcomes instead of ORIF in combination with subtalar arthrodesis.

There is currently no evidence for the gold standard treatment of calcaneal fractures with combined tarsal coalitions. Due to the satisfactory results of this case, authors conclude that in case with prior asymptomatic coalitions, singular ORIF without subtalar arthrodesis may be performed.

Ethical Details: The patient gave his written informed consent for the case presentation.

Conflicts of Interest: None declared.

References

1. Crim JR, Kjeldsberg KM. Radiographic diagnosis of tarsal coalition. *AJR Am J Roentgenol.* 2004;**182**(2):323-8.
2. Ozyurek S, Guler F, Turan A, Kose O. Symptomatic talar beak in talocalcaneal coalition. *BMJ Case Rep.* 2013;**2013**.
3. Umul A. MRI Findings of Talocalcaneal Coalition: Two Case Reports. *Acta Inform Med.* 2015;**23**(4):248-9.
4. Wahnert D, Gruneweller N, Evers J, Sellmeier AC, Raschke MJ, Ochman S. An unusual cause of ankle pain: fracture of a talocalcaneal coalition as a differential diagnosis in an acute ankle sprain: a case report and literature review. *BMC Musculoskelet Disord.* 2013;**14**:111.
5. Moe DC, Choi JJ, Davis KW. Posterior subtalar facet coalition with calcaneal stress fracture. *AJR Am J Roentgenol.* 2006;**186**(1):259-64.
6. Solomon LB, Ruhli FJ, Taylor J, Ferris L, Pope R, Henneberg M. A dissection and computer tomograph study of tarsal coalitions in 100 cadaver feet. *J Orthop Res.* 2003;**21**(2):352-8.
7. Hughes A, Brown R. Talar body fracture associated with unrecognised talocalcaneal coalition. *Foot Ankle Surg.* 2010;**16**(2):e4-7.
8. Kim DH, Berkowitz MJ. Fracture of the calcaneus associated with talocalcaneal coalition. *Foot Ankle Int.* 2004;**25**(6):426-8.
9. Chodos MD, Campbell JT. Intra-articular calcaneal fracture with tarsal coalition treated with open reduction, internal fixation, and isolated subtalar arthrodesis: a case report. *Foot Ankle Int.* 2007;**28**(9):1017-20.

Open Access License

All articles published by Bulletin of Emergency And Trauma are fully open access: immediately freely available to read, download and share. Bulletin of Emergency And Trauma articles are published under a Creative Commons license (CC-BY-NC).